


Correction of Astigmatism by a Single-Focus Toric Intraocular Lens during Cataract Surgery: Refractive State and Visual Acuity



M.A. Alnoelaty Almasri



V.C. Stebnev

Samara State Medical University
Chapaevsky str., 89, Samara, 443099, Russian Federation

ABSTRACT

Ophthalmology in Russia. 2021;18(4):852–856

Purpose: the main purpose of study is to obtain a better visual outcome after implantation of a monofocal toric IOLs by accurate measurement, calculations and visual assessment. **Methods.** Fifty eyes with astigmatism of more than 2.5 D were included in a hospital-based prospective study. A biometric evaluation is done by Lenstar. Barette's toric calculation method is used to measure toric IOLs power. In a vertical position, preoperative axis marking was done by both bubble marker and direct slit beam. On table, in a horizontal position, axis marking was reassessed. After phacoemulsification, a monofocal Supra Phob toric IOL was implanted and rotated to match corneal axis marking. Best-corrected visual acuity was measured postoperatively at 1 and 3 months. **Results.** Reduction of mean of refractive astigmatism was reported postoperatively from 4.0 ± 0.79 preoperatively to 0.7 ± 0.28 at 1 month and 0.6 ± 0.27 at 3 months postoperatively. In whole, 96 % has residual astigmatism less than 1 D at 3 months postoperatively, while 8 % eyes had residual astigmatism more than 1 D. In whole, 76 % patients had IOLs rotation of less than or equal to 5° , 20 % patients had it between 6° and 10° and 4 % eyes had more than 10° at day 7 postoperatively, in which repositioning of IOLs was required. **Conclusion.** To reduce postoperative residual astigmatism after toric IOLs and to get better results, accurate measurement of parameters and proper calculation are essential.

Keywords: phacoemulsification, rotation, calculator, stability, visual acuity

For citation: Alnoelaty Almasri M.A., Stebnev V.C. Correction of Astigmatism by a Single-Focus Toric Intraocular Lens during Cataract Surgery: Refractive State and Visual Acuity. *Ophthalmology in Russia*. 2021;18(4):852–856. <https://doi.org/10.18008/1816-5095-2021-4-852-856>

Financial Disclosure: No author has a financial or property interest in any material or method mentioned

There is no conflict of interests



Использование однофокусной торической интраокулярной линзы для коррекции астигматизма в процессе хирургии катаракты: рефракционное состояние и острота зрения

М.А. Альноелати Альмасри, В.С. Стебнев

ФГБУЗ ВО «Самарский государственный медицинский университет»
Министерства здравоохранения Российской Федерации
ул. Чапаевская, 89, Самара, 443099, Российская Федерация

РЕЗЮМЕ

Офтальмология. 2021;18(4):852–856

Цель: получение наилучшего визуального результата после имплантации монофокальной торической ИОЛ путем точных измерений, расчетов и визуальной оценки. **Методы.** Пятьдесят глаз с астигматизмом более 2,5 D были включены в проспективное исследование, проведенное в Самарской областной клинической больнице. Биометрическую оценку проводили с помощью оптического биометра Lenstar. Для измерения мощности торических ИОЛ был использован калькулятор Barret. В вертикальном положении предоперационную маркировку оси выполняли как пузырьковым маркером, так и прямым щелевым лучом. В горизонтальном положении маркировка оси была уточнена. После фактоэмульсификации была имплантирована монофокальная Supra Phob ИОЛ и повернута в соответствии с маркировкой оси роговицы. Острота зрения с наилучшей коррекцией была измерена после операции через 1 и 3 месяца. **Результаты.** До операции средний показатель рефракционного астигматизма составлял $4,0 \pm 0,79$, через 1 месяц после операции — $0,7 \pm 0,28$, а через 3 месяца снизился до $0,6 \pm 0,27$. В целом у 96 % пациентов остаточный астигматизм был менее 1 D через 3 месяца после операции, в то время как у 4 % — более 1 D. В целом у 76 % пациентов вращение ИОЛ было меньше или равно 5° , у 20 % астигматизм находился в диапазоне от 6° до 10° , и лишь в 4 % наблюдалось вращение ИОЛ более 10° на 7-й день после операции, что потребовало последующей репозиции ИОЛ. **Вывод.** Для уменьшения послеоперационного остаточного астигматизма после имплантации торической ИОЛ и получения лучших результатов необходимы точное измерение параметров и правильный расчет биометрических показателей.

Ключевые слова: фактоэмульсификация, вращение, стабильность, острота зрения, калькулятор

Для цитирования: Альноелати Альмасри М.А., Стебнев В.С. Использование однофокусной торической интраокулярной линзы для коррекции астигматизма в процессе хирургии катаракты: рефракционное состояние и острота зрения. *Офтальмология*. 2021;18(4):852–856. <https://doi.org/10.18008/1816-5095-2021-4-852-856>

Прозрачность финансовой деятельности: Никто из авторов не имеет финансовой заинтересованности в представленных материалах или методах

Конфликт интересов отсутствует

INTRODUCTION

Cataract is clouding of the lens in the eye that normally affects vision. It is the leading cause of blindness and the second leading cause of vision impairment [1]. Around of 15–29 % cataract patients have pre-existing astigmatism more than 1.5 D, while 3–15 % of cataract eyes have greater than 2 D [2]. So, reducing astigmatism probably improve visual outcome after cataract surgery.

Implantation of traditional intraocular lens in cataract patients during surgery may need additional refractive procedures, like limbal relaxing incisions, corneal incisions in steep meridian, and femtosecond laser-associated astigmatic keratotomy [3], which are associated with some complications such as lack of precision, delayed wound healing, and corneal epithelial defects.

Using toric intraocular lens, which is made of hydrophobic acrylic material with stable force haptic design, is more predictable and precise than corneal or limbal relaxing incisions and no need to additional refractive procedures [4]. Accurate and proper preoperative biometric calculation using lenstar or IOL Master determine the success of toric IOLs.

However, Rotational stability in the capsular bag for longer period also constitute important factor to get optimal results after implantation. It has been estimated that 1 of off-axis rotation results in a loss of cylindrical power up to

3.3 % [5]. Rotational stability is crucial factor in the efficacy of toric IOLs.

Most important disadvantage of toric IOLs after ordinary cataract surgery is IOL rotation. Incomplete viscoelastic clearance [6], capsulorrhexis size, early postoperative intraocular pressure fluctuations [7], material and design of IOL [8] are most frequent causes of IOL rotation. A capsular bag fibrosis, which occur in first 3 months of implantation, could also lead to IOL rotation [9].

After taking into consideration surgically induced astigmatism SIA [10], calculation of required toric IOL and postoperative residual astigmatism can be done. If posterior corneal astigmatism is ignored, total corneal astigmatism in with-the-rule and against-the-rule is overestimated and underestimated, respectively [11]. According to several studies, Barrett universal II formula is greatly better than other formulas in prediction of accurate postoperative refraction [12, 13]. By comparing toric IOLs with other methods which correct astigmatism, a better visual acuity with spectacle independence and less residual astigmatism was obtained with toric IOLs [14].

METHODS

This interventional prospective study carried out at Samara Regional clinical hospital named after V.D. Seredavin. Fifty eyes having senile cataract with corneal astigmatism

M.A. Alnoelaty Almasri, V.C. Stebnev

Contact information: Mohamad Aeham Alnoelaty Almasri noelatyaham@yahoo.com

Correction of Astigmatism by a Single-Focus Toric Intraocular Lens during Cataract Surgery...

more than 2.5 D were involved in our research. We just started using toric IOLs and wanted to appreciate changes in astigmatism before and after surgery. The study was approved by institutional ethical committee and abided the declaration of Helsinki. A Written informed consent was taken from each patient and individual data (age, gender, address, contact, telephone number) was collected. Every patient was asked about his /her chief complaints, previous history of injury, ocular surgeries, and history of systemic diseases. Patients who understood the study and willing to sign consent form were included in the study. In other hand, patients with irregular astigmatism, corneal disease, abnormal iris, pupil abnormalities, glaucoma, any kind of retinal disease, strabismus, previous ocular trauma or surgery were excluded.

Using Snellen S Visual acuity Chart (Appasamy Associate, India) or illiterate E chart (UCVA), and best-corrected visual acuity (BCVA) of all patients were measured. External eye examination, pupillary reaction evaluation, and anterior segment examination were performed with a slit lamp (Appasamy Associate, India). Lens opacification classification system was used to grade stages of senile cataract.

Nuclear opalescence 2 (NC2), cortical 1(c1), and posterior subcapsular (p1) were the minimum score of cataract in each category. Under full mydriasis with 90 D (volk, USA), optic disc and macula were examined by slit lamp biomicroscopy. Indirect ophthalmoscopy (AAI07, India) was applied by 20 D (Volk, USA).

All patients underwent keratometry, axial length, optical anterior chamber depth, lens thickness, corneal diameter, and IOL power using Lenstar Optical Biometer (Haag-Streit, USA). Upon previous cataract surgeries performed by the surgeon, surgeon's SIA was calculated and was 0.5 D.

To calculate the toric IOLs power with its axis and an appropriate model, an online toric IOL Calculator based on Barrett method (available at: www.apacrs.org/) was used. A monofocal Supra phob toric IOLs with yellow hydrophobic acrylic material and cylinder powers of 1.5 D to 6 D were used.

Measurement of blood pressure, urine routine and microscopy, complete haemogram, fasting blood sugar, and postprandial blood sugar and echocardiogram for physical fitness were done for all patients. All patients underwent routine preoperative preparation after getting fitness in pre-anesthetic check up.

In sitting position, axis was marked on a slit lamp using both bubble marker and direct slit lamp with a marker pen preoperatively. To prevent cyclotorsion, preoperative axis marking was rechecked again. The incision location was determined as recommended by a toric calculator or on the temporal side (as in traditional cases). In sleeping position, axis marking was confirmed using degree marker and bubble marker. In all cases, a monofocal Supra Phob Toric IOL was implanted in bag under viscoelastic substance and rotated to match its marking with corneal axis marking.

Postoperatively, following up patients were done on day 1 and day 7, 1 month and 3 months. One surgeon did all operations while both preoperative and postoperative evaluation were done by the another person single handedly. A comparison taken between intended axis and present axis by postoperative corneal markings and postoperative photographs taken on all follow-ups to check any IOL rotation. Metal ring marker with axis marking was used postoperatively to check axis. UCVA, BCVA, detailed slit lamp examination, autorefractometry, axial length, and keratometry using Lenstar were assessed in all patients. Residual sphere was 0.25–0.5 D, and the main focus of this study was on the residual cylinder; hence, residual sphere was not considered.

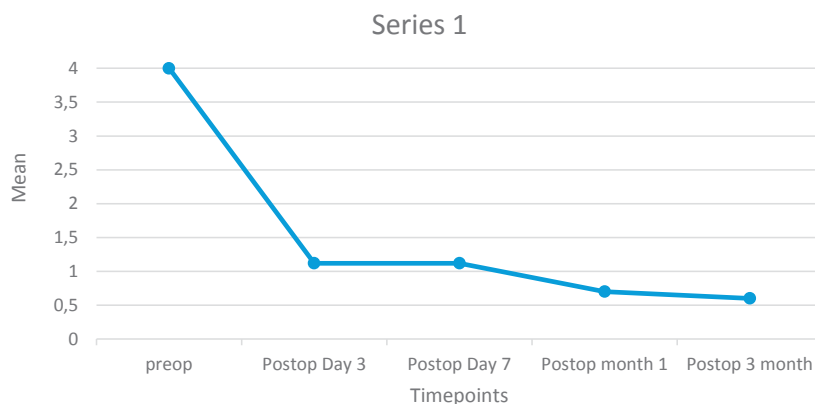


Fig. 1. Mean and standard deviation (SD) of refractive astigmatism preoperatively and postoperatively is revealed, N = 50. Refractive astigmatism reduced from 4.0 ± 0.97 to 0.3 ± 0.27 on 3 months postoperatively

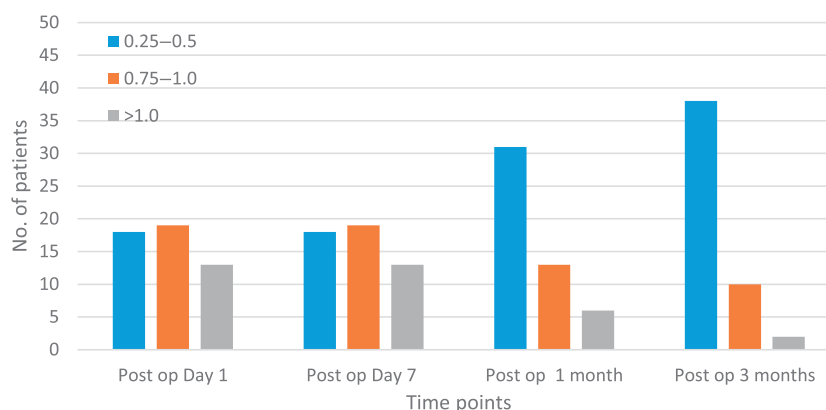


Fig. 2. Residual astigmatism on all follow ups is demonstrated. The residual astigmatism was 0.5D or less in 18 (36 %) patients on postop day1 and 7. Forty-eight (96 %) patients had residual astigmatism 1D or less, while 2 (4 %) patients had residual astigmatism more than 1D at 3 months

Eyes showing IOL rotation up to 10° on follow-up were left as it is, whereas those above 10° needed IOL repositioning. The rotation of IOL may be due to the material of IOL and presence of viscoelastic after surgery. Berdahl & Hardten Toric IOL calculator was used to determine the axis of IOL repositioning. This calculator required preoperative and postoperative keratometry. It also required operative assessment details, postoperative refraction, anterior chamber depth, and axial length. All the above parameters along with axial length were assessed again in the cases where there was rotation. The reassessment of axial length helped us in determining the accurate axis for IOL repositioning.

RESULTS

Figure 1 shows mean and standard deviation (SD) of refractive astigmatism preoperatively and postoperatively. Mean and SD of preoperative refractive astigmatism was 4.0 ± 0.97 . It reduced to 1.12 ± 1.20 on day 1 and 7, 0.7 ± 0.28 on 1 month and 0.6 ± 0.27 on 3 months postoperatively.

Figure 2 shows residual astigmatism on all follow-ups. The residual astigmatism in our study was 0.50 D or less in 18 (36 %) patients on postop day 1 and 7. At 1 month, 31 (62 %) patients had residual astigmatism of 0.50 D or less, 13 (26 %) patients had residual astigmatism between 0.75 and 1 D, while 6 (12 %) patients had residual astigmatism more than 1 D. At 3 months, 38 (76 %) patients had residual astigmatism of 0.50 D or less, 10 (20 %) patients had residual astigmatism between 0.75 and 1 D, while 2 (4 %) patients had residual astigmatism more than 1 D.

Table 1 shows toric IOL misalignment after toric IOL implantation. Thirty eight (76 %) patients had toric IOL rotation less than or equal to 5° on postop day 1 and day 7, while 40 (80 %) had it on postop 1 and 3 months. Ten (20 %) patients had toric IOL rotation between 6° and 10° on all follow-ups. Two (4 %) patients had toric IOL rotation more than 10° on postop day 1 and day 7. Toric IOL repositioning was done in these two cases. None of the patients had toric IOL rotation more than 10° on postop 1 and 3 months.

Table 2 shows the residual cylinder and axis rotation of the two eyes with IOL rotation more than 10° . Toric IOL rotation more than 10° was seen two (4 %) eyes postoperatively, which required IOL repositioning. In the first case, the toric IOL was found to have rotated by 60° with a residual cylinder of 4.0 D. IOL repositioning was performed. In the second case the toric IOL was found to have rotated by 54° with a residual cylinder of 5 D. IOL repositioning was performed after 1 week.

DISCUSSION

Refractive outcome of cataract surgery is significantly influenced by preexisting corneal astigmatism. Using of Toric IOL is one of several surgical options to correct corneal astigmatism during cataract surgery. An important advancement in modern cataract surgery is stable and effective toric IOL implantation in the capsular bag during routine phacoemulsification cataract surgery without any corneal procedures.

In our study, mean and SD of preoperative refractive astigmatism was 4.0 ± 0.97 . Mean and SD of refractive astigmatism on postoperative day 1 and 7 was 1.12 ± 1.20 . Mean and SD of postoperative refractive astigmatism was 0.7 ± 0.28 on 1 month, while it was 0.6 ± 0.27 at 3 months.

Similarly, M. Khan et al. [15] (2015) evaluated that the mean preoperative keratometric cylinder was 3.78 ± 1.0 D in group 1 and postoperative refractive value was 1.2 ± 0.68 D on day 7. The study included three groups out of which group 1 matched our study and was taken for comparison. Group 1 included 25 eyes with corneal astigmatism more than 2.50 D and cataract receiving a toric monofocal IOL. They stated that the preoperative refractive cylinder and keratometric cylinder values can be used interchangeably.

In our study, 44 (88 %) patients had residual astigmatism less than 1 D at 1 month, while 46 (92 %) patients had residual astigmatism less than 1 D at 3 months. Thirty-nine (78 %) had residual astigmatism between 0.50 and 3 D. Two (4 %) patients had residual astigmatism more than 3 D.

Similarly, B. Kramer et al. [16] (2016) evaluated the causes for residual astigmatism after toric IOL implantation. They found that 70 % of all cases had residual astigmatism between 0.50 and 2 D; 90 % cases were between 0.50 and 3 D.

N. Hirnschall et al. [17] (2017) compared the astigmatism reducing effect of a toric IOL and peripheral corneal relaxing incisions. We compared our observations with the toric IOL implanted eyes. In total, 96 % eyes had residual astigmatism less or equal to 1 D in toric IOL group, and 4 % eyes had residual astigmatism more than 1 D. It was comparable to our study.

In our study, 27 (54 %) patients had toric IOL rotation less than or equal to 5° on postop day 1 and day 7. Thirty-three (66 %) had it on postop 1 and 3 months. IOL rotation of 10° or less was seen in 36 (72 %) patients on postop day 1 and day 7.

Similarly, T. Miyake et al. [18] (2014) studied the clinical outcomes and rotational stability of toric IOL to correct preexisting corneal astigmatism in cataract patients. In total, 75.4 % patients had toric IOL rotation within $\pm 5^\circ$ off axis on postop day 1 and 73.8 % had it at 1 week.

J.H. Farooqui et al. [19] (2015) found that IOL misalignment of less than or equal to 5° was present in 46 (71.9 %)

Table 1. Misalignment after toric IOL implantation

Toric IOL Rotation	Number of patients			
	Postop Day 1	Postop Day 7	Postop Month 1	Postop Month 3
$\leq 5^\circ$ off axis	38	38	40	40
$6-10^\circ$ off axis	10	10	10	10
$>10^\circ$ off axis	2	2	0	0

Table 2. Residual cylinder of two cases with IOL rotation more than 10°

Number of eyes	Residual cylinder (D)	Axis rotation (degrees)
1	4D	50
1	5D	54

eyes, while 60 (93.8 %) showed IOL misalignment of 10° or less which was comparable to our study.

CONCLUSION

Among various modalities to correct preexisting corneal astigmatism with cataract surgery, Phacoemusification with toric IOL implantation is one of the most convenient method to correct preexisting corneal astigmatism with cataract surgery in a single procedure. Refractive astigmatism reduced significantly after toric IOL implantation. Visual performance was almost similar to the compared

studies. In total, 92 % patients had residual astigmatism less than or equal to 1.00 D at 3 months postoperative. Patients tolerated slight residual refractive error very well. Accurate measurement of parameters and the proper method of calculation reduce the postoperative residual astigmatism after toric IOL implantation. Toric IOL implantation is safe, effective, predictable, and precise method to correct pre-existing corneal astigmatism and cataract. It had good rotational stability. It improves postoperative BCVA to 6/6 without glasses, providing high levels of patient's satisfaction.

REFERENCES

- William Yan, Wei Wang, Peter van Wijngaarden. Longitudinal changes in global cataract surgery rate inequality and associations with socioeconomic indices. *Clin Exp Ophthalmol*. 2019 May;47(4):453–460.
- Xianwen Xiao, Fang Tian, Zhonghua Yan Ke Za Zhi. Clinical study of optical quality after implantation of aspheric toric intraocular lens in cataract surgery. 2015 Apr;51(4):263–269.
- Clayton Blehm, Richard Potvin. Evaluating Refractive and Visual Outcomes After Bilateral Implantation of an Apodized Diffractive Multifocal Toric Intraocular Lens with a Moderate Add in the Dominant Eye and a Higher Add in the Fellow Eye. *Clin Ophthalmol*. 2020 Apr 9;14:1035–1041.
- Manpreet Kaur, Farin Shaikh, Ruchita Falera. Optimizing outcomes with toric intraocular lenses. *Indian J Ophthalmol*. 2017 Dec;65(12):1301–1313.
- Xue K., Jolly J.K., Mall S.P., Haldar S., Rosen P.H., MacLaren R.E. Real world refractive outcomes of toric intraocular lens implantation in a United Kingdom National Health Service setting. *BMC Ophthalmol*. 2018;18:30.
- Myers T.D., Olson R.J. Comparison of the effects of viscoelastic agents on clinical properties of the Unifolder lens injection system. *J Cataract Refract Surg*. 1999;25:953–958.
- Pereira F.A., Milverton E.J., Coroneo M.T. Miyake. Apple study of the rotational stability of the AcrySof toric intraocular lens after experimental eye trauma. *Eye (Lond)*. 2010;24:376–378.
- Kevin L Waltz, Kristen Featherstone, Linda Tsai. Clinical outcomes of TECNIS toric intraocular lens implantation after cataract removal in patients with corneal astigmatism. *Ophthalmology*. 2015 Jan;122(1):39–47.
- Mana Tehrani, H Burkhard Dick, Frank Krummenauer, Gudrun Pfirrmann. Capsule measuring ring to predict capsular bag diameter and follow its course after foldable intraocular lens implantation. *J Cataract Refract Surg*. 2003 Nov;29(11):2127–2134.
- Hill W., Potvin R. Monte Carlo simulation of expected outcomes with the AcrySof® toric intraocular lens. *BMC Ophthalmol*. 2008;8:22.
- Zheng T., Chen Z., Lu Y. Influence factors of estimation errors for total corneal astigmatism using keratometric astigmatism in patients before cataract surgery. *J Cataract Refract Surg*. 2016;42:84–94.
- Jack X Kane, Benjamin Connell. A Comparison of the Accuracy of 6 Modern Toric Intraocular Lens Formulas. *Ophthalmology*. 2020 Nov;127(11):1472–1486.
- Kieren Darcy, David Gunn, Shokufeh Tavassoli, John Sparrow. Assessment of the accuracy of new and updated intraocular lens power calculation formulas in 10 930 eyes from the UK National Health Service. *J Cataract Refract Surg*. 2020 Jan;46(1):2–7.
- Kessel L., Andresen J., Tendal B., Erngaard D., Flesner P., Hjortdal J. Toric intraocular lenses in the correction of astigmatism during cataract surgery: A systematic review and meta analysis. *Ophthalmology*. 2016;123:275–286.
- Khan M.I., Ching S.W., Muhtaseb M. The use of toric intraocular lens to correct astigmatism at the time of cataract surgery. *Oman J Ophthalmol*. 2015;8:38–43.
- Kramer B.A., Berdahl J.P., Hardten D.R., Potvin R. Residual astigmatism after toric intraocular lens implantation: Analysis of data from an online toric intraocular lens back calculator. *J Cataract Refract Surg*. 2016;42:1595–1601.
- Hirnschall N., Gangwani V., Crnej A., Koshy J., Maurino V., Findl O. Correction of moderate corneal astigmatism during cataract surgery: Toric intraocular lens versus peripheral corneal relaxing incisions. *J Cataract Refract Surg*. 2014;40:354–361.
- Miyake T., Kamiya K., Amano R., Iida Y., Tsunehiro S., Shimizu K. Long term clinical outcomes of toric intraocular lens implantation in cataract cases with preexisting astigmatism. *J Cataract Refract Surg*. 2014;40:1654–1660.
- Farooqui J.H., Koul A., Dutta R., Shroff N.M. Management of moderate and severe corneal astigmatism with AcrySof toric intraocular lens implantation Our experience. *Saudi J Ophthalmol*. 2015;29:264–269.

ABOUT THE AUTHORS

Samara State Medical University
Alnoelaty Almasri Mohamad Aeham
postgraduate
Chapaevsky str., 89, Samara, 443099, Russian Federation

Samara State Medical University
Stebnev Vladimir C.
MD, Professor of the ophthalmology department
Chapaevsky str., 89, Samara, 443099, Russian Federation