

Aniridia, aphakia accompanied by retinal detachment: problem and its ways of solution



Hanyukov VN



Hazennov AN

The S. Fyodorov Eye Microsurgery Federal State Institution Orenburg branch, Salmishskaya street, 17, Orenburg, 460047, Russia

SUMMARY

Purpose Evaluation of the results of various treatment tactics of patients with post-traumatic retinal detachment pathology combined with aniridia and aphakia. **Patients and methods.** The analysis of four clinical cases of surgical treatment of post-traumatic retinal detachment in conjunction with aniridia and aphakia was carried out. There was used a gradual approach of optic-reconstructive surgery: vitreoretinal stage by the standard method 23-25 Ga with tamponade of vitreous cavity with silicone oil in two different ways. In one case, full eyeball tamponade was made, and in the other one it was made up to the diaphragm formed of polypropylene sutures. At the final stage — iridolenticular diaphragm was implanted (Reper-NN, Russia). **Results.** In all cases, early postoperative reaction proceeded with the phenomena of fibrino-plastic iridocyclitis, which corresponded to the severity of the initial state and the volume of surgical intervention. Periods of observation of patients in the postoperative period ranged from 3 to 12 months. In three cases where the diaphragm was formed from polypropylene sutures there was noticed full retina adaptation, wherein silicone oil, introduced in the vitreous cavity, did not penetrate into the anterior chamber during the entire period of observation. In one case, where there was a complete eyeball tamponade with silicone oil epithelial and endothelial corneal dystrophy developed. Such an outcome of a clinical case, despite high functional results, is apparently related to the severity of the initial state, the need to re-intervention for recurrent retinal detachment and relatively early stages of iridolenticular diaphragm implantation. **Conclusion.** Reconstructive surgery of posttraumatic aniridia and aphakia combined with retinal detachment requires a multistage approach. Reconstruction of anterior segment of the eye is preferably to carry out in long-term periods as after the trauma so after surgical treatment of retinal detachment.

Choice of the method of eye cavity tamponade by silicone oil depends on the severity of the initial state, at that the formation of the diaphragm from polypropylene sutures provides longer tamponing by silicone, reduces the risk of postoperative complications.

Key words: aniridia, aphakia, retinal detachment, iridolenticular diaphragm, tamponade with silicone oil.

Financial Disclosure: No author has a financial or property interest in any material or method mentioned. There is no conflict of interests

Ophthalmology in Russia. — 2014. — Vol. 11, No3. — P. 89–93

INTRODUCTION

Penetrating and blunt trauma of the eyeball, usually are accompanied by damage of both the anterior segment: cornea, iris, lens, and the posterior segment: as destruction, hemophthalmia, retinal detachment. The combination of post-traumatic changes of anterior and posterior segments of the eye significantly complicates the optical-reconstructive surgery for restoration of normal correlation of damaged structures [1; 2; 3]. One of the main tasks of combined operations in injuries of iridolenticular diaphragm and the posterior segment of the eye is its recovery [4]. To compen-

sate functional disorders of the iris different methods of extraocular, intraocular and intracorneal diaphragming are used [5; 2; 6; 7; 4; 8; 9]. Application of modern technologies of surgery on the posterior segment of the eye is a standard procedure. Difficulties arise when we need plugging of vitreous cavity. One of the basic plugging agents is silicone oil [10; 11]. Proceeding from this, special attention should be devoted to combined injuries of the eyeball at full aniridia, aphakia and retinal detachment. In this situation it is necessary to solve several problems, such as the choice of simultaneous or phased tactics of optic-reconstructive sur-

gery, possibility of application of silicone tamponade of vitreous cavity and a diaphragming method [12; 13; 14; 15].

PURPOSE

Evaluation of the clinical results at various treatment tactics of patients with post-traumatic retinal detachment pathology combined with aniridia and aphakia.

PATIENTS AND METHODS

There was carried out a retrospective analysis of four cases of concomitant pathology of anterior segment of the eye (aniridia, aphakia) and retinal detachment.

Patients — males aged 24 to 54 years. In all cases there has been a traumatic eye injury. In 2 patients — the consequences of penetrating injury of the cornea with the presence of an intraocular foreign body, which previously had been performed primary surgical treatment (PST) with removal of intraocular foreign body in community-based hospitals. In two other cases, there was a severe contusion of the eyeball. All patients came in Orenburg branch in the remote terms after primary surgical treatment or injury (from 30 days to 6 months).

Surgical treatment (posterior closed subtotal vitrectomy) was performed using the apparatus Associate 6000 (D. O. R. C.) by technology 23-25 Ga. In all cases, vitreoretinal phase of surgery was carried out by the standard method, which was to restore transparency of media, locate retinal damages, tamponade by perfluororganic compounds (PFOC) followed by endolasercoagulation of retina (ELCR) and replaced by silicone oil 5700 cSt. Silicone oil tamponade was performed in two ways. In one embodiment, the cavity of the eyeball was filled completely (Fig. 1). In the other — a diaphragm was formed from polypropylene filaments of 10/0 [16]. When forming diaphragm conjunctiva was separated from the limbus and, departing from it 1 mm, it was fixed trans-scleral by U-shaped sutures. Thus, the diaphragm was formed in the shape of a grid with cells 2×2 mm, which divided the eye to the anterior chamber and the vitreous cavity (Fig. 2). In these cases the silicone oil was introduced

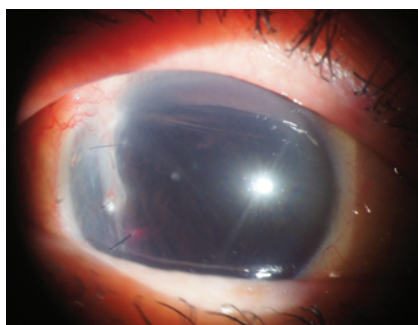


Fig. 1 Full tamponade of eyeball by silicone oil.

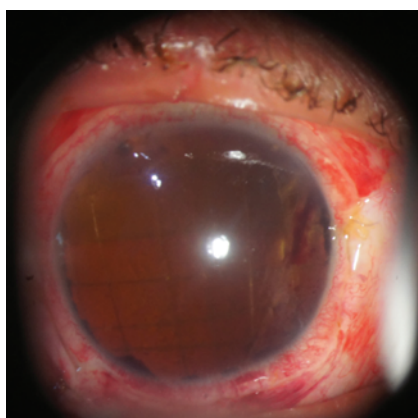


Fig. 2 Eyeball with diaphragm formed of polypropylene filaments (tamponade by silicone oil on the 1st day after surgery).

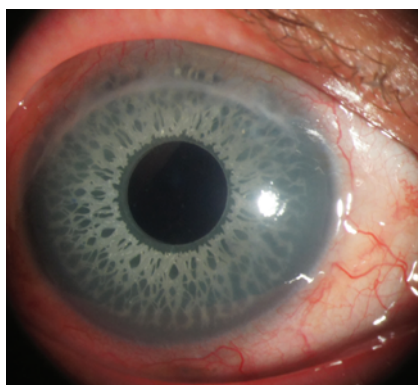


Fig. 3 State after implantation of iridolenticular diaphragm.

into the eye cavity up to the level of the formed diaphragm and was maintained by the surface tension force [17], without penetrating into the anterior chamber, which excluded the contact with the corneal endothelium. At the time of PFOC replacement by silicone there was injected viscoelastic corneal protector into the anterior chamber, which resolved subsequently.

At the final stage iridolenticular diaphragm and MIOL-iris were implanted (Reper-NN, Russia) (Fig. 3).

Clinical case 1

Patient Zh. Diagnosis: OD — Sequelae of blunt trauma of the eye with subconjunctival scleral rupture and abasement of veils, primary surgical treatment, aniridia, aphakia, hemophthalmus, retinal detachment, choroidal rupture.

On admission: visual acuity OD — light perception with the correct projection, OS — 1,0; IOP: OD — 12 mm Hg, OS — 19 mm Hg. The patient underwent vitrectomy, blood was removed, retinal rupture was localized, retina was mobilized to PFOC, endolasercoagulation of retina was made with subsequent replacement by silicone oil, which completely plugged the cavity of the right eye. On the 4th day after surgery visual acuity of the right eye was 0.2 with correction; IOP — 16 mm Hg.

At control examination after 3 months flat retinal detachment was diagnosed in the lower quadrant with repeated traction epiretinal fibrosis. Revision of vitreous cavity was made, epiretinal membranes were removed, additional endolasercoagulation of retina on PFOC was held with simul-

taneous implantation of iridolenticular diaphragm. PFOS then was successively replaced by silicone oil. Visual acuity at admission was 0,04, at discharge — 0,01. At biomicroscopy silicone wasn't observed in the anterior chamber, when viewed from the fundus retina was adherent (Fig. 3). However, in 6 months after the surgery epithelial-endothelial corneal dystrophy developed in the patient.

Clinical case 2

Patient A. Diagnosis: OD — Sequelae of a penetrating wound of the cornea, aniridia, aphakia, organized hemoph-

thalamus, retinal detachment.

On admission: visual acuity OD — light perception with the correct projection, OS — 1,0; IOP: OD — 16 mm Hg, OS — 21 mm Hg. There was performed vitrectomy, excision of epiretinal membranes, retinal mobilization on PFOC, retinal endolasercoagulation of the right eye. Diaphragm was formed of polypropylene sutures according to the above procedure, after which PFOC was replaced by silicon. At discharge OD: visual acuity was 20 cm due to the fingers; IOP — 26 mm Hg. At examination of fundus — retina was adherent, at biomicroscopy — silicone wasn't observed in the anterior chamber. At the control examination in 1 month after the surgery state of the right eye was without changes, visual acuity improved to 0,02. Aspiration of silicone oil was planned in 3 months.

Clinical case 3

Patient A. Diagnosis: OD — Sequelae of blunt trauma of the eye, iridodialysis, dislocation of the lens into the vitreous, organized hemophthalmus, retinal detachment.

On admission visual acuity: OD — light perception with the correct projection, OS — 1,0; IOP: OD — 20 mm Hg, OS — 18 mm Hg. There was performed vitrectomy, lensectomy, excision of membranes, mobilization of retina on PFOC with retinal endolasercoagulation. From the optic disc to the extreme periphery of the outer side, the prevalence was about 90°, there was a dense chorioretinal adhesion and submacular choroidal rupture. The patient was formed a diaphragm of polypropylene sutures, then PFOS was replaced by silicone oil. Visual acuity at discharge has not changed. On examination — retina was adherent, at biomicroscopy — silicone wasn't observed in the anterior chamber. At the control examination in 3 months functions were without any changes.. Aspiration of silicone oil was planned in 3 months.

Clinical case 4

Patient A. Diagnosis: Sequelae of blunt trauma of the eye, complete iridodialysis, dislocation of the lens into the vitreous, hemophthalmus, trauma retinal detachment with rupture from the ora serrata in the upper quadrants more than 100°, secondary hypertension of the right eye.

On admission visual acuity: OD — light perception with correct projection, OS — 1,0; IOP: OD — 31 mm Hg, OS — 13 mm Hg. There was performed vitrectomy, lensectomy, excision of membranes, mobilization of retina on PFOC with retinal endolasercoagulation. The patient was formed a diaphragm of polypropylene sutures, then PFOS was replaced by silicone oil. At discharge visual acuity: OD was 15 cm due to the fingers; IOP — 15 mm Hg. On examination — retina was adherent, at biomicroscopy — silicone wasn't observed in the anterior chamber. At the control examination in 3 months visual acuity improved up to 0,1. Aspiration of silicone oil was planned in 1 month.

THE RESULTS AND DISCUSSION

In all cases, early postoperative reaction proceeded with the phenomena of fibrino-plastic iridocyclitis, which corresponded to the severity of the initial state and the volume of surgical intervention. Against steroid and antibiotic therapy phenomena of inflammation were stopped in an average to 5-7 day. In one case, there was noticed the phenomenon of hypertension, but against hypotensive therapy and partial discharge of viscoelastic from the anterior chamber through the paracentesis of the cornea at 6 hours it became able to stop hypertension.

Periods of observation of patients in the postoperative period ranged from 3 to 12 months. In the three cases where the diaphragm was formed by polypropylene filaments, there was a complete adhesion of the retina, where in the silicone oil, introduced in the vitreous cavity, during the entire period of observation did not penetrate into the anterior chamber. In 2 patients central vision remained, and in the third one — it was peripheral because of central scar and submacular choroidal rupture. Subsequently, all patients were planned implantation of iridolenticular diaphragm in 12 months after removal of silicone oil in accordance with the existing guidelines [7].

In one case, where there was complete tamponade of eyeball by silicon oil, epithelial-endothelial corneal dystrophy developed.

Such an outcome of a clinical case, in spite of the high functional results, apparently related to the severity of the initial state, the need to re-intervention for recurrent retinal detachment and relatively early stages of iridolenticular diaphragm implantation.

Based on the observations of the patient data, it should be noted that in severe cases, usage of diaphragm from polypropylene filaments allows applying a longer silicone tamponade that possibly gives an opportunity to reduce both cases of recurrence and large destruction of endothelial cells.

CONCLUSIONS

Modern equipment and microsurgical technologies contribute to the rehabilitation of patients with severe post-traumatic combined ophthalmopathology.

Reconstructive surgery of posttraumatic aniridia and aphakia combined with retinal detachment requires a multistage approach.

Reconstruction of anterior segment of the eye is preferably to carry out in long-term periods as after the trauma so after surgical treatment of retinal detachment.

The choice of method of eye cavity tamponade with silicone oil depends on severity of the initial state, at that formation of diaphragm from polypropylene filaments provides longer plugging by silicone, reduces the risk of postoperative complications.

REFERENCES

1. Boyko E.V., Sosnovskiy S.V., Kulikov A.N., Shamrey D.V. [Modern possibilities of organ-vitreoretinal surgery in the outcome of severe eye injury]. *Sovremennye vozmozhnosti organosokhrannoy vitreoretinal'noy khirurgii v iskhode tyazheloy travmy glaza*. [Health. Medical ecology. Science]. Zdorov'e. Meditsinskaya ekologiya. Nauka. 2012; 1-2: 68]. 2012; 1-2: 68. (in Russ.).
2. Zapuskalov I.V., Krivosheina O.I. [Modern trends in reconstructive surgery of traumatic lesions of the anterior segment of the eye (literature review)]. *Sovremennye tendentsii rekonstruktivnoy khirurgii travmaticheskikh povrezhdeniy perednego otrezka glaza (obzor literatury)*. [Ophthalmosurgery 2013;2:59-61]. *Oftal'mokhirurgiya* 2013; 2: 59-61. (in Russ.).
3. Ioshin I.E., Egorova E.V., Sobolev N.P. [Reconstructive surgery of traumatic injuries of the iris and the lens using artificial eye diaphragm]. *Rekonstruktivnaya khirurgiya travmaticheskikh povrezhdeniy raduzhki i khrustalika s ispol'zovaniem iskusstvennoy diafragmy glaza*. [Ophthalmosurgery. 2002; 2: 15]. *Oftal'mokhirurgiya*. 2002; 2: 15] (in Russ.).
4. Takhchidi Kh.P., Shkvorchenko D.O., Kakunina S.A., Novikov S.V. [Surgical treatment of cocomitant injury of anterior and posterior segments of the eye using the new model of barrier-optical membrane]. *Khirurgicheskoe lechenie sochetannogo povrezhdeniya perednego i zadnego segmentov glaza s ispol'zovaniem novoy modeli bar'erno-opticheskoy membrany*. [Ophthalmosurgery 2009;3:12-15]. *Oftal'mokhirurgiya* 2009; 3: 12-15.] (in Russ.).
5. Aznabaev M.T. [Plastic surgery of the iris]. *Plasticheskaya khirurgiya raduzhki*. Ufa, 1997, 156 s. (in Russ.).
6. Pozdeeva N.A. [A new model of artificial iridolenticular diaphragm for correction of large defects of the iris (clinical and functional results of implantation)]. [Annals of ophthalmology]. *Novaya model' iskusstvennoy iridokhrustalikovoy diafragmy dlya korrektsii bol'shikh defektov raduzhnoy obolochki (kliniko-funktsional'nye rezul'taty implantatsii)*. *Vestnik oftal'mologii*. 2013; 129. (6): 38-44.] (in Russ.).
7. Ioshin I.E., Egorova E.V., Tolchinskaya A.I., Sobolev N.P. [Surgical treatment of traumatic aniridia and aphakia using iridium-lens diaphragm]. *Khirurgicheskoe lechenie travmaticheskoy afakii i aniridii s ispol'zovaniem irido-khrustalikovoy diafragmy*. [New in ophthalmology]. *Novoe v oftal'mologii*. 2000; 1: 34-35.] (in Russ.).
8. Alio J.L., Rodriguez A.E., Toffaha B.T. Keratopigmentation (corneal tattooing) for the management of visual disabilities of the eye related to iris defects // *Br.J. Ophthalmol.* 2011, 95: 1397-1401.
9. Prosdocimo G., Foltran F. Ophtec iris diaphragm IOL implantation in aphakic vitrectomized eyes with traumatic iris defects // Congress of the ESCRS, 22 nd: book of abstracts. Paris, 2004. P.155.
10. Zakharov V.D., Bessarabov A.N., Kostina N.E., Uzunyan D.G. [Prevention of light silicone migration into the anterior chamber during silicone tamponade of vitreous cavity with aphakia]. *Profilaktika migratsii legkogo silikona v perednyuyu kameru v protsesse silikonovoy tamponady vitreal'noy polosti pri afakii*. [Ophthalmosurgery]. *Oftal'mokhirurgiya*. 2008; 2: 34-40.] (in Russ.).
11. Takhchidi Kh.P., Metayev S.A., Glinchuk N.Ya., Vinnik N.A. [Actual problems of endovitreoretal tamponade in vitreal surgery]. [New in ophthalmology]. *Aktual'nye problemy endovitreoretal'noy tamponady v vitreal'noy khirurgii*. *Novoe v oftal'mologii*. 2005; 3: 45-55.] (in Russ.).
12. Pozdeyeva N.A., Frolychev I.A., Pashtayev N.P. [Vitreoretinal surgery at patients with posttraumatic aniridia]. *Vitreoretinal'naya khirurgiya u patsientov s posttravmaticheskoy aniridiei*. [Ophthalmosurgery]. *Oftal'mokhirurgiya* 2012; 3: 42-47]. (in Russ.).
13. Takhchidi Kh.P., Shkvorchenko D.O., Kakunina S.A., Novikov S.V., Leont'eva G.D., Selifanov Yu.V., Uzunyan D.G. [Surgical treatment of combined injuries of anterior and posterior segments of the eye using the new model of barrier-optical membrane]. *Khirurgicheskoe lechenie sochetannogo povrezhdeniya perednego i zadnego segmentov glaza s ispol'zovaniem novoy modeli bar'erno-opticheskoy membrany*. [Ophthalmosurgery]. *Oftal'mokhirurgiya*. 2009: 12-15. (in Russ.).
14. Rossi T., Boccassini B., Iossa M. et al. Combined pars plana vitrectomy and artificial iris diaphragm implant after globe rupture. *Graefes Arch. Clin. Exp. Ophthalmol.* 2009; 247: 439-443.
15. Thumann G., Kirchhof B., BartzSchmidt K. U. et al. The artificial iris diaphragm for vitreoretinal silicone oil surgery // *Retina*. 1997, 17. (4): 330-337.
16. Man-Seong Seo et al. Triangular transchamber suture // *J. Cataract Refract. Surg.* 2001, 27: 172-173.
17. Zakharov V.D. [Vitreoretinal surgery]. *Vitreoretinal'naya khirurgiya*. M., 2003, 180 p.] (in Russ.).